

Pulmonary Cryptococcosis Complicated by Pneumococcal Pneumonia Co-Infection with Influenza A Virus

Yoshihiro Kobashi, Daisuke Yoshioka, Shigeki Kato and Toru Oga

Department of Respiratory Medicine, Kawasaki Medical School, Japan

Article history

Received: 24-01-2021

Revised: 02-04-2021

Accepted: 06-04-2021

Corresponding Author:

Yoshihiro Kobashi

Department of Respiratory
Medicine, Kawasaki Medical
School, Japan

Email: yoshihiro@med.kawasaki-m.ac.jp

Abstract: A 73-year-old man visited Kawasaki Medical School Hospital with complaints of cough and fever persisting for five days. He was diagnosed with myasthenia gravis in 2010 and had received immunosuppressive treatment for eight years. He presented with infiltration shadows in the bilateral middle and lower lung fields. Because both influenza A virus antigen and urinary pneumococcal pneumonia antigen were positive in laboratory findings, he was diagnosed with pneumococcal pneumonia co-infection with influenza A on admission. We administered peramivir and sulbactam/ampicillin after admission. Although the inflammatory response improved, infiltration shadows did not improve. We performed bronchoscopic examination and obtained the diagnosis of the complication of pulmonary cryptococcosis by transbronchial lung biopsy. He was treated with fluconazole for six months for pulmonary cryptococcosis and he showed improvement without adverse reactions. We report an interesting immunocompromised patient with pulmonary cryptococcosis complicated by pneumococcal pneumonia co-infection with influenza A.

Keywords: Pulmonary Cryptococcosis, Pneumococcal Pneumonia, Influenza A Virus, Co-Infection

Introduction

Background

Pulmonary cryptococcosis is a fungal respiratory infection that occurs after the inhalation of *Cryptococcus spp.*. *Cryptococcus* can occur in immunocompetent hosts, but is most common in immunocompromised hosts (Setianingrum *et al.*, 2019; Zhang *et al.*, 2012). Immunocompromising factors are as follows: Acquired Immunodeficiency Syndrome (AIDS), malignant disease, organ transplantation, corticosteroid therapy and diabetes mellitus (Setianingrum *et al.*, 2019; Huang *et al.*, 2016).

On the other hand, it is difficult to distinguish pulmonary cryptococcosis from bacterial pneumonia or pulmonary mycobacterial disease because of this similar clinical features and radiological characteristics in immunocompromised patient (Guimaraes *et al.*, 2013; Choi *et al.*, 2017). We report an immunocompromised patient with a delayed diagnosis of pulmonary cryptococcosis due to difficulty in the differential diagnosis of pneumococcal pneumonia co-infection with influenza A virus.

Case Presentation

A 73-year-old man visited Kawasaki Medical School Hospital with complaints of a cough and fever persisting for five days. He had a smoking history of 30 cigarettes per day for fifty years. Concerning ecological information, he did not have a bird at home and did not live near a large population of birds. It was not clear whether he lived in an area with abundant decomposing plants. He was diagnosed with myasthenia gravis in 2010 and hypertension, diabetes mellitus and prostate cancer in 2017. He had received immunosuppressive treatment such as tacrolimus and corticosteroid therapy for eight years since the diagnosis of myasthenia gravis. On physical examination, his blood pressure was 139/73 mmHg, heart rate was 103 per minute and regular, body temperature was 39.1°C and SpO₂ was 94% (O₂ 4L). Chest auscultation revealed coarse crackles in the bilateral lower lung fields. There was no neurological finding suggesting meningitis such as neck stiffness. Regarding the laboratory findings on admission, the inflammatory response with leukocytosis was positive (white blood cell count: 10680/μL, C-reactive protein: 5.64 mg/dL). Although mild hypoalbuminemia (2.8 g/dL)

was noted, serum globulin was within the normal limits. Procalcitonin showed mild elevation (0.60 ng/mL). A urinary pneumococcal antigen test (Binax NOW *Streptococcus pneumoniae* Urinary Antigen Test, Abbott Corporation) and influenza A antigen test (Quicknavi-Flu2 Test, Otsuka Corporation) were positive. Gram stain of the sputum showed gram-positive cocci and culture of the purulent sputum grew *Streptococcus pneumoniae* (2+), but culture using Sabouraud Dextrose Agar of the sputum of the sputum did not lead to the growth of any fungus. *S. pneumoniae* isolated from this patient was sensitive to penicillin G and we judged it as Penicillin-Sensitive *Streptococcus Pneumoniae* (PSSP) according to the Clinical and Laboratory Standards Institute (CLSI) definition of susceptibility (CLSI, 2018). Although Cerebrospinal Fluid (CSF) examination was also performed, the number of inflammatory cells ranged within normal limits.

Regarding the radiological findings on admission, chest X-ray showed infiltration shadows in the bilateral middle and lower lung fields (Fig. 1). Chest Computed Tomography (CT) on admission revealed infiltration shadows with an air-bronchogram and ground-glass opacity with peripheral zone dominance in both lung fields (Fig. 2a and 2b).

We diagnosed this patient with pneumococcal pneumonia co-infection with influenza A virus. Firstly, we initiated Treatment Using Sulbactam/Ampicillin

(SBT/ABPC) for pneumococcal pneumonia and peramivir for influenza A virus infection. We continued treatment using corticosteroid and tacrolimus for myasthenia gravis simultaneously. Although the clinical symptoms such as fever and cough and the inflammatory response were improved 14 days after admission, the infiltration shadows did not change. Therefore, we performed bronchoscopy in order to examine whether there were other complicating diseases 14 days after admission. Subsequently, the smear and culture examinations of common bacteria, fungus and acid-fast bacilli of brushing and Bronchoalveolar Lavage Fluid (BALF) from right middle and lower lobes were all negative, but histological findings showed organizing pneumonia with masson bodies (Fig. 3a) on Hematoxylin-Eosin (HE) staining and *Cryptococcus* was recognized in the masson bodies in Grocott staining (Fig. 3b). Serum *Cryptococcus neoformans* Antigen (SCA) (Latex agglutination method, SRL Corporation) was elevated 512-fold. We made a diagnosis of pulmonary cryptococcosis and organizing pneumonia due to *S. pneumoniae* and influenza A virus infection. After treatment for pneumococcal pneumonia co-infection with influenza A virus, we initiated treatment using Fluconazole (FLCZ) for pulmonary cryptococcosis and continued it for six months. Chest X-ray (Fig. 4a and 5b) and Chest CT (Fig. 4b and 5a) showed the improvement of infiltration shadows after six months.

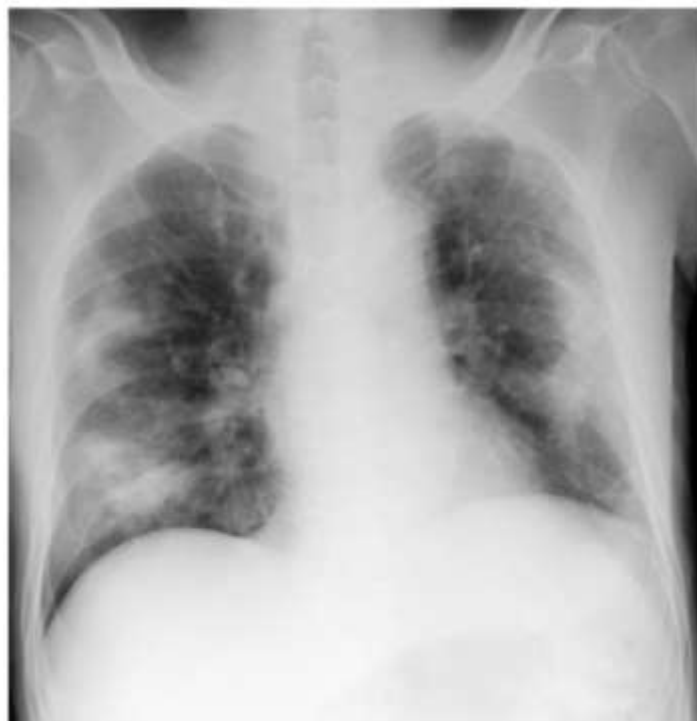

Fig. 1: Chest X-ray on admission showed an infiltration shadow in the bilateral middle and lower lung fields

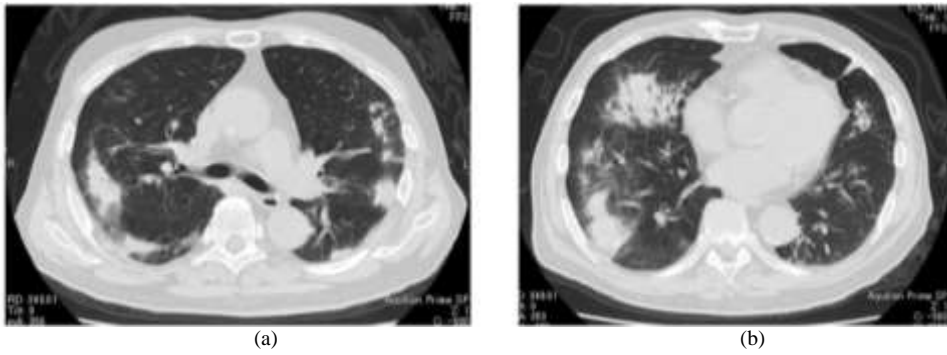


Fig. 2: Chest CT on admission showed infiltration shadows with an air-bronchogram and ground-glass opacity in the peripheral part, dominant in both lung fields

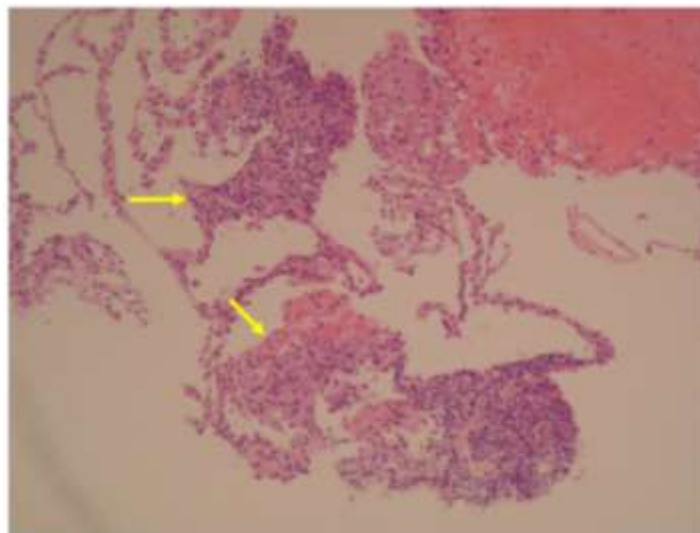


Fig. 3: Histological findings of Transbronchial Lung Biopsy (TBLB) from the right B⁸ and B⁹ showed organizing pneumonia with mason bodies (Hematoxylin-eosin staining, $\times 40$)

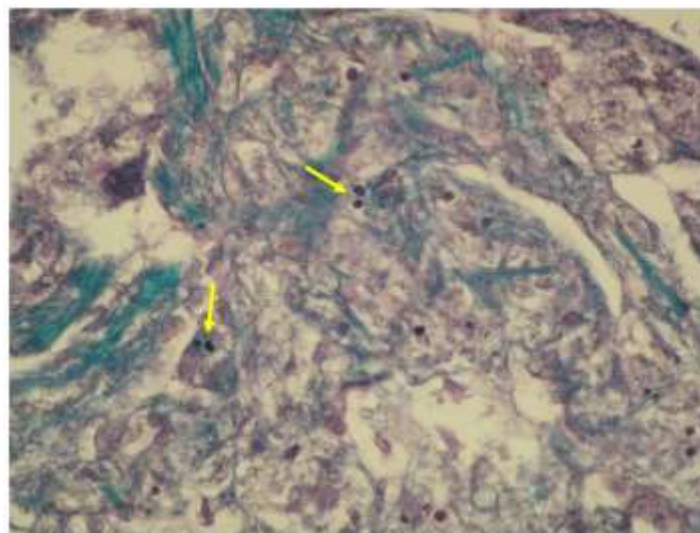


Fig. 4: Histological findings of TBLB from the right B⁸ and B⁹ showed Cryptococcus bodies (arrow) (Grocott staining, $\times 200$)

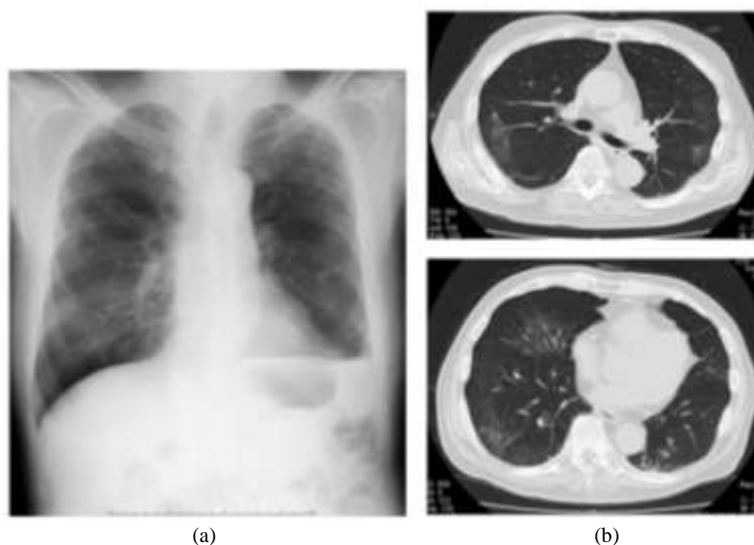


Fig. 5: Chest X-ray and chest CT at the conclusion of antifungal therapy revealed the improvement of infiltration shadows

Discussion

In recent years, the incidence of *Cryptococcus* infection has been increasing in immunocompromised patients such as patients with AIDS and those received organ transplantation or immunosuppressive treatment such as corticosteroid drugs (Rigby and Glanville, 2012; Singh *et al.*, 2008; Kohno *et al.*, 2015; Xie *et al.*, 2015). In our case, the use of corticosteroid drugs was an important predisposing factor. When the cellular immune system had been destroyed, macrophages could not remove *Cryptococcus* microorganisms and so they spread into the lung, central nervous system and multiple other organs. Because positive responses of influenza A virus antigen and urinary pneumococcal antigen were recognized in the laboratory findings on admission, we delayed the diagnosis of pulmonary cryptococcosis in this case. In fact, it was previously reported that early diagnosis is difficult and 85% of patients were misdiagnosed with pneumonia, lung cancer, or pulmonary tuberculosis on admission (Xie *et al.*, 2015).

Concerning the radiological findings, pulmonary cryptococcosis can present with various patterns and is influenced by the immune status of the patient. In previous reports concerning radiologic features of patients with immunocompromised and immunocompetent status, while cavitation within nodules, ground-glass opacity and parenchymal consolidation were significantly more frequent in immunocompromised than immunocompetent patients (Chang *et al.*, 2006; Xie *et al.*, 2015; Kishi *et al.*, 2006; Sui *et al.*, 2020), air-bronchograms were common in immunocompetent patients (Chang *et al.*, 2006). On the other hand, the extent of lesions tended to be larger and their distribution was predominantly in the peripheral part of the lung in immunocompromised

patients (Xie *et al.*, 2015; Qu *et al.*, 2012). Because the radiological findings on chest CT showed infiltration shadows with air-bronchogram and ground-glass opacity in the dominant peripheral part in both lung field in our patient, being slightly different from previously described common radiological findings, it was difficult to differentiate the condition from other pulmonary diseases based solely on radiological findings.

Regarding the pathological findings, the lesion in patients who did not have underlying immunodeficiency or predisposing conditions usually remains localized and becomes granulomatous and then nodular and fibrocaseous. On the other hand, in immunocompromised patients, progressive pulmonary or disseminated cryptococcosis develops and there is often a mild reactive pattern with little inflammation. Cryptococci multiply profusely, displacing normal tissues and form cystic lesions composed of heavily encapsulated organisms that elicit little surrounding reaction (Tomashefski *et al.*, 2008). Because our patient received long-term immunosuppressive treatment and had not only pulmonary cryptococcosis, but also complicated pneumococcal pneumonia co-infection with influenza a virus, we think that the histological findings showed an atypical pattern such as organizing pneumonia with masson bodies, without forming a granuloma and noted cryptococcus within masson bodies.

Regarding SCA in laboratory findings, it is a useful tool to diagnose cryptococcal infection and monitor disease activity (Xie *et al.*, 2015; Kohno *et al.*, 2015). Although the sensitivity and specificity of SCA were excellent for the diagnosis of pulmonary cryptococcosis (93-100 and 93-98%, respectively) (Setianingrum *et al.*, 2019), reported that only 39% of non-HIV

immunocompromised patients showed positive results for SCA (Aberg *et al.*, 1999). However, because SCA was elevated (512-fold) on admission in our patient and this decreased according to the good response to treatment, it was a good biomarker to diagnose or treat pulmonary cryptococcosis. Recent studies on antigen detection tests have progressed and capsular polysaccharides of *Cryptococcus* can now be detected and quantified in samples of body fluids such as serum, CSF, BALF and urine specific anti-*Cryptococcus neoformans* antisera (Chen *et al.*, 2014; Diaz and Nguyen, 2010). Three formats of cryptococcal antigen detection tests using the latex agglutination test, the enzyme-linked immunoassay and the lateral flow immunoassay are available (Chen *et al.*, 2014; Pongsai *et al.*, 2010; McMullan *et al.*, 2012).

The American Thoracic Society (ATS) recommends fluconazole or itraconazole for the treatment of mild to moderate pulmonary cryptococcosis in immunocompromised patients for 6-12 months and amphotericin B plus flucytosine or a lipid formulation of amphotericin B for the treatment of severe pulmonary cryptococcosis or pulmonary cryptococcosis combined with central nervous system infection in immunocompromised patients for 6-10 weeks (Limper *et al.*, 2011). Therefore, we performed antifungal therapy using fluconazole in our case for six months according to this guideline.

There is a limitation of this case report. When we performed bronchoscopy in order to examine whether there were other complicating diseases, the smear and culture examination of common bacteria, fungus and acid-fast bacilli of bronchoscopic specimens such as brushing and BALF could be performed to obtain negative results on culture, but they were not performed for the transbronchial lung biopsy materials. Therefore, we could not perform sufficient examinations to investigate the species of *Cryptococcus* that caused pulmonary cryptococcosis in this patient. We think that it is important to identify the species of *Cryptococcus* to obtain more information about the ecology and clarify the contamination source in order to integrate with epidemiological data.

We think that he developed pneumococcal pneumonia co-infection with influenza A virus because of the isolation of *Streptococcus pneumoniae* from purulent sputum and positive response of urinary pneumococcal antigen and influenza A virus antigen on admission, finally, we became aware of the high titer of SCA and activity performed a bronchoscopic examination two weeks later. Therefore, we could achieve a correct diagnosis of pulmonary cryptococcosis in spite of various radiological findings due to pulmonary cryptococcosis in an immunocompromised patient receiving long-term corticosteroid and tacrolimus therapy. It is important to actively perform specific antigen detection tests using various clinical specimens or invasive examination such as bronchoscopy to achieve early diagnosis and provide appropriate treatment.

Conclusion

We reported an interesting case of pulmonary cryptococcosis complicated by pneumococcal pneumonia co-infection with influenza A virus. We should be careful when infectious diseases due to multiple causative microorganisms are present in immunocompromised patients receiving immunosuppressive treatment and it is necessary to conduct a positive microbiological examination to achieve a correct diagnosis.

Author's Contributions

Yoshihiro Kobashi: Corresponding author of this paper and designed and wrote the whole manuscript.

Daisuke Yoshioka and Shigeki Kato: Reviewing and editing.

Toru Oga: Reviewing and editing, supervision.

Ethics

This article is original and contains unpublished material. The corresponding author confirms that all of the other authors have approved the manuscript and no ethical issues existed.

References

- Aberg, J. A., Mundy, L. M., & Powderly, W. G. (1999). Pulmonary cryptococcosis in patients without HIV infection. *Chest*, 115(3), 734-740. <https://www.sciencedirect.com/science/article/abs/pii/S0012369216356434>
- Chang, W. C., Tzao, C., Hsu, H. H., Lee, S. C., Huang, K. L., Tung, H. J., & Chen, C. Y. (2006). Pulmonary cryptococcosis: comparison of clinical and radiographic characteristics in immunocompetent and immunocompromised patients. *Chest*, 129(2), 333-340. <https://www.sciencedirect.com/science/article/abs/pii/S0012369215387547>
- Chen, S. C. A., Meyer, W., & Sorrell, T. C. (2014). *Cryptococcus gattii* infections. *Clinical Microbiology Reviews*, 27(4), 980-1024. <https://cmr.asm.org/content/27/4/980.short>
- Choi, H. W., Chong, S., Kim, M. K., & Park, I. W. (2017). Pulmonary cryptococcosis manifesting as diffuse air-space consolidations in an immunocompetent patient. *Journal of Thoracic Disease*, 9(2), E138. <https://www.ncbi.nlm.nih.gov/pmc/articles/PMC5334071/>
- CLSI. (2018). Performance Standards for Antimicrobial Susceptibility Testing. CLSI supplement M100. 28th edition. Wayne, P.A.: Clinical and Laboratory Standards Institute.

- Diaz, M. R., & Nguyen, M. H. (2010). Diagnostic Approach Based on Capsular Antigen, Capsule Detection, β -Glucan, and DNA Analysis. *Cryptococcus: from human pathogen to model yeast*, 547-564.
- Guimaraes, M. D., Marchiori, E., Meirelles, G. D. S. P., Hochegger, B., Santana, P. R. P., Gross, J. L., ... & Godoy, M. C. B. (2013). Fungal infection mimicking pulmonary malignancy: clinical and radiological characteristics. *Lung*, 191(6), 655-662. <https://link.springer.com/article/10.1007%2Fs00408-013-9506-0>
- Huang, J., Lan, C. Q., Li, H. Y., Lin, Q. H., Liu, J. F., & Wen, H. (2016). Retrospective analysis of 117 chinese patients with pulmonary cryptococcosis. *Chest*, 149(4), A124. [https://journal.chestnet.org/article/S0012-3692\(16\)00747-9/abstract](https://journal.chestnet.org/article/S0012-3692(16)00747-9/abstract)
- Kishi, K., Homma, S., Kurosaki, A., Kohno, T., Motoi, N., & Yoshimura, K. (2006). Clinical features and high-resolution CT findings of pulmonary cryptococcosis in non-AIDS patients. *Respiratory Medicine*, 100(5), 807-812. <https://www.sciencedirect.com/science/article/pii/S0954611105003756>
- Kohno, S., Kakeya, H., Izumikawa, K., Miyazaki, T., Yamamoto, Y., Yanagihara, K., ... & Ashizawa, K. (2015). Clinical features of pulmonary cryptococcosis in non-HIV patients in Japan. *Journal of Infection and Chemotherapy*, 21(1), 23-30. <https://www.sciencedirect.com/science/article/abs/pii/S1341321X14003080>
- Limper, A. H., Knox, K. S., Sarosi, G. A., Ampel, N. M., Bennett, J. E., Catanzaro, A., ... & Stevens, D. A. (2011). An official American Thoracic Society statement: treatment of fungal infections in adult pulmonary and critical care patients. *American Journal of Respiratory and Critical Care Medicine*, 183(1), 96-128. <https://www.atsjournals.org/doi/full/10.1164/rccm.2008-740ST>
- McMullan, B. J., Halliday, C., Sorrell, T. C., Judd, D., Sleiman, S., Marriott, D., ... & Chen, S. C. (2012). Clinical utility of the cryptococcal antigen lateral flow assay in a diagnostic mycology laboratory. *PLoS One*, 7(11), e49541. <https://journals.plos.org/plosone/article?id=10.1371/journal.pone.0049541>
- Pongsai, P., Atamasirikul, K., & Sungkanuparph, S. (2010). The role of serum cryptococcal antigen screening for the early diagnosis of cryptococcosis in HIV-infected patients with different ranges of CD4 cell counts. *Journal of Infection*, 60(6), 474-477. <https://www.sciencedirect.com/science/article/abs/pii/S0163445310000836>
- Qu, Y., Liu, G., Ghimire, P., Liao, M., Shi, H., Yang, G., ... & Wang, G. (2012). Primary pulmonary cryptococcosis: evaluation of CT characteristics in 26 immunocompetent Chinese patients. *Acta Radiologica*, 53(6), 668-674. <https://journals.sagepub.com/doi/abs/10.1258/ar.2012.110612>
- Rigby, A. L., & Glanville, A. R. (2012). Miliary pulmonary cryptococcosis in an HIV-positive patient. *American Journal Of Respiratory And Critical Care Medicine*, 186(2), 200-201. <https://www.atsjournals.org/doi/full/10.1164/ajrccm.186.2.200>
- Setianingrum, F., Rautemaa-Richardson, R., & Denning, D. W. (2019). Pulmonary cryptococcosis: a review of pathobiology and clinical aspects. *Medical Mycology*, 57(2), 133-150. <https://academic.oup.com/mmy/article/57/2/133/5133472?login=true>
- Singh, N., Alexander, B. D., Lortholary, O., Dromer, F., Gupta, K. L., John, G. T., ... & Husain, S. (2008). Pulmonary cryptococcosis in solid organ transplant recipients: clinical relevance of serum cryptococcal antigen. *Clinical Infectious Diseases*, 46(2), e12-e18. <https://academic.oup.com/cid/article/46/2/e12/461301?login=true>
- Sui, X., Huang, Y., Song, W., Zheng, F., Wang, X., Xu, X., ... & Jin, Z. (2020). Clinical features of pulmonary cryptococcosis in thin-section CT in immunocompetent and non-AIDS immunocompromised patients. *La Radiologia Medica*, 125(1), 31-38. <https://link.springer.com/article/10.1007/s11547-019-01088-8>
- Tomashefski, J. F., Cagle, P. T., Farver, C. F., & Fraire, A. E. (Eds.). (2008). *Dail and Hammar's Pulmonary Pathology: Volume I: Nonneoplastic Lung Disease*. Springer New York. <https://link.springer.com/book/10.1007/978-0-387-68792-6>
- Xie, L. X., Chen, Y. S., Liu, S. Y., & Shi, Y. X. (2015). Pulmonary cryptococcosis: comparison of CT findings in immunocompetent and immunocompromised patients. *Acta Radiologica*, 56(4), 447-453. <https://journals.sagepub.com/doi/abs/10.1177/0284185114529105>
- Zhang, Y., Li, N., Zhang, Y., Li, H., Chen, X., Wang, S., ... & Yung, R. C. (2012). Clinical analysis of 76 patients pathologically diagnosed with pulmonary cryptococcosis. *European Respiratory Journal*, 40(5), 1191-1200. <https://erj.ersjournals.com/content/40/5/1191.short>